

# Percutaneous Renal Access with Patients in a Modified Supine Position

Yi-Hsin Chang<sup>1</sup>, Te-Chen Tsai<sup>1</sup>, Han -Ming Chen<sup>2</sup>, Fang-Sheng Tsai<sup>3</sup>, Wai-Yan Wong<sup>3</sup>

<sup>1</sup>Department of Urology and <sup>2</sup>Surgery, Ten-Chan General Hospital, <sup>3</sup>Department of Urology Ten-Chen General Hospital Taoyuan, Taiwan, R.O.C.

**OBJECTIVES:** We advocate a modified supine position for a percutaneous renal approach which is justified due to its safety and convenience.

**MATERIALS AND METHODS:** From January 2003 to June 2006, 134 percutaneous nephrostomies or drainage of renal cysts were performed in 72 males and 62 females at our institution. Patient ages ranged 23~81 (mean, 49.5) years. Under local or sedative anesthesia, a patient was placed in a supine position with a rolled-up towel below both the ipsilateral shoulder and hip, leaving ample space beneath the flank. The skin was punctured in a posterior axillary line under ultrasonographic guidance.

**RESULTS:** The average operative time was  $14.3 \pm 2.1$  (range, 5~32) minutes. The renal puncture was similar to that used in the prone position under ultrasonography. Our success rate was compatible to that of the formal prone position. We experienced 3 failures in placing the nephrostomy catheter (pigtail) with loss of path during dilation of the tract. No serious complications, such as colon perforation, occurred.

**CONCLUSIONS:** Percutaneous renal access under ultrasonographic guidance with a patient in the modified supine position offers another safe and convenient way to reach the kidneys. (JTUA 18:87-89, 2007)

*Key words:* percutaneous nephrolithotomy, supine.

## INTRODUCTION

The prone position has long been adopted for percutaneous nephroscopy as this position provides sufficient space for freely manipulating the renolescope within the intrarenal collecting system.<sup>1,2</sup> However several inevitable drawbacks such as postural changes due to boredom and discomfort were encountered when patients were placed in such a position. Anesthesiologists are sometimes reluctant to put patients under intravenous sedation in a prone position as it is harder to maintain a patent airway. Several studies have claimed that changing the routine practice of percutaneous nephrolithotomy (PCNL) from a prone to a supine position has numerous benefits and is safe and effective.<sup>3,4</sup> We modified the patient's position under the guidance of ultrasound to demonstrate that such a modification is effective and safe and saves time in patients who require sedation.

## MATERIALS AND METHODS

From January 2003 to June 2006, 134 consecutive percutaneous nephrostomies or drainage of renal cysts were performed in 72 males and 62 females in a modified supine position. Patients' ages ranged 3~81 (mean, 49.5) years and weights were 42~95 (mean, 66.3) kg with proportional heights. Seventy-five patients who had renal cysts received percutaneous drainage of those cysts in the right kidney in 43 and in the left kidney in 32. The remaining 59 patients had hydronephrosis owing to ureteral stones in 46 and other ureteral obstructions in 13 patients (Table 1).

Under local anesthesia or intravenous sedation, a patient is placed in the modified supine position with a roll of towel below both the ipsilateral shoulder and hip, leaving ample space beneath the flank. The operative table is flexed in order to stretch the flank and hence widen the space and keep the skin taut, which facilitates making the puncture. This results in a mild oblique position of 30°. The ipsilateral arm is laid over the thorax (Fig. 1).

The skin is punctured along a posterior axillary line under ultrasonographic guidance. The procedure is much easier in patients with renal cyst in which the 20-cm puncture needle is inserted directly into the kidney,

Address reprint requests and correspondence to:  
Dr Wai-Yan Wong, MD, Department of Urology, Ten-Chen General Hospital, 356 Zhong-Shan N. Road, Sec. 1, Yangmei, Taoyuan, Taiwan 326, R.O.C.  
Tel: 886-3-4782350 ext. 62008 Fax: 886-3-4782149  
E-mail: josephwo.tw@yahoo.com.tw

and the fluid is drained via the syringe. In cases with hydropelvis, a 0.035-inch (x.xx-mm) guide wire is passed through the puncture needle with correct placement into the renal pelvis; then we dilate the tract to 12 Fr. and inserted an 8-Fr. nephrostomy catheter. The patient remains in the same modified supine position for the entire procedure and the surgeon can either sit or stand according to his/her own preference.

**RESULTS**

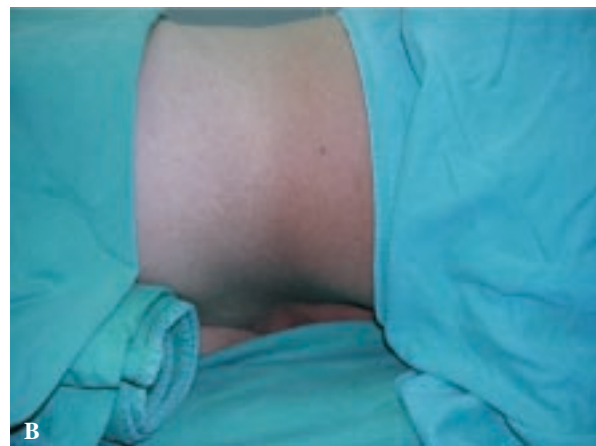
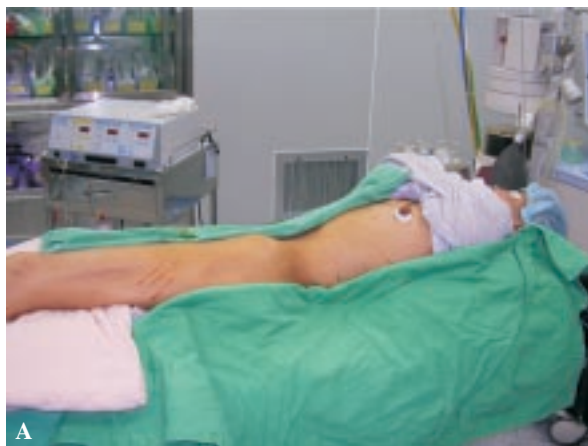The mean operative time was 14.3 ± 2.1 (range, 5-32) minutes. All 75 patients for drainage of cysts underwent the procedure smoothly under local anesthesia. Intravenous sedation and local anesthesia were respectively adopted in 36 and 23 patients who received a nephrostomy. The patients who received local anesthesia included 15 who needed an emergent high diversion due to infective hydronephrosis and another 8 who had a high anesthetic risk (American Society of Anesthesiologists class III). We experienced 4 failures with loss of path during dilation of the tract. No colon perforation occurred in any of our patients treated in the modified supine position. We also noted that no pneumothorax or hydrothorax occurred.

**DISCUSSION**

Most surgeons who perform percutaneous nephrostomies place their patients in a prone position.<sup>1</sup> <sup>2</sup> In addition to providing sufficient space for extensive manipulation of the endoscope within the intrarenal collecting system, they also rationally try to avoid any damage to the adjacent intra-abdominal organs, especially the colon. In spite of the slight chance, colon perforation is still encountered in such a position even in experts' hands.<sup>5-7</sup> In a cadaveric study, Valdiva et al. proposed that when a patient is supine, the colon is not pushed to the posterior but instead to the anterior due to reduced compression of the anterior abdominal wall.<sup>8</sup> When applying the puncture needle under sonographic guidance,<sup>9</sup> the approach actually follows an imaginary line crossing the kidney and vertebral center, without touching the colon. From our experience with 134 attempts in conjunction with Valdiva's and series from the other ethnic Chinese populations,<sup>3,10</sup> no splanchnic injuries were noted. This suggests that when a patient is placed in a supine position, the chance of perforating the colon is negligible if the nephrostomy tract is meticulously built up along the posterior axillary line. The slight chance of any undesirable intra-abdominal organ injuries is thus comparable to the traditional prone

**Table 1.** Etiologies for percutaneous renal puncture and choices of anesthesia

Etiology	Local anesthesia	Intravenous sedation
Renal cyst	75	none
Ureteral stone with hydronephrosis	15	31
Other ureteral obstructions	8	5



**Fig. 1A, B.** The modified supine position in which the patient is tilted about 30°.

approach.

We prefer performing the nephrostomy with patients sedated unless they are physically unfit for intravenous anesthesia or have had inadequate stomach emptying time, as it dramatically reduces the pain and fear of the patients compared to the circumstance when patients are awake and alert. The introduction of such a modified posture has increased the willingness to apply intravenous sedation in patients by anesthesiologists as they can maintain a patent airway without needing to tilt the head and face up. Furthermore, there are risks of iatrogenic injuries when changing the position of a patient. The neck or extremities, especially the arms, can be injured during a postural change.

If a ureteroscopic examination is needed during the procedure, the modified supine position offers a great advantage of shortening the operative time. This is particularly useful in cases in which a high diversion and ureteroscopic lithotripsy are concomitantly performed under general or spinal anesthesia. A combined modified supine position and lithotomy position with the hip of the elevated side flexed while the contralateral hip is extended provides optimal access for transurethral ureteroscopy to obtain maximal endoscopic exposure to intrarenal and ureteral sites.

Our modification of the percutaneous approach differs from Valdiva's method<sup>10</sup> in several ways. First, instead of placing a bag under the lumbar region, we elevate the shoulder and the hip separately with a bag or roll, leaving ample space beneath the flank. We believe that such a free space facilitates manipulation of the Amplatz sheath with a greater range of movement compared to the original design by Valdiva in which the bag might hinder the sheath from bending downwards. Second, Valdiva stressed that it is important to avoid any tendency toward an oblique position. Our modification of placing the patient in a 30° oblique position creates more space and increased freedom for the nephroscopic manipulation. Most important, as the puncture is determined parallel to the operative table, it forms an inclination of 30° with the trunk and further secures the tract built in the retroperitoneum with less chance of injuring the colon. We noted that such a modified su-

pine position with free space beneath the flank is more versatile than the original supine position.

## CONCLUSIONS

Our results indicate that percutaneous nephroscopy under ultrasonographic guidance with a patient in the modified supine position is safe, and it is easy to justify its application.

## REFERENCES

1. Lehman T, Bagley D. Reversed lithotomy: modified prone position for simultaneous nephroscopic and ureteroscopic procedures in women. *Urology* 1988;32: 529-32.
2. Coleman CC. Percutaneous nephrolithotomy, approaches. In: Amplatz K, Lange PH, eds. *Atlas of Endourology*. Chap 14. Chicago, IL: Yearbook Medical Publisher 1986:115-29.
3. Shoma AM, Eraky I, El-Kenawy MR, El-Kappany HA. Percutaneous nephrolithotomy in the supine position: technical aspects and functional outcome compared with the prone technique. *Urology* 2002;60:388-92.
4. Ng MT, Sun WH, Cheng CW, Chan SY. Supine position is safe and effective for percutaneous nephrolithotomy. *J Endourol* 2004;18:469-74.
5. Netto NR, Lemos GC, Fiuza JL. Colon perforation following percutaneous nephrolithotomy. *Urology* 1988;32: 223-6.
6. Segura JW, Patterson DE, Leroy AJ, Williams HJ Jr, Barrett DM, Benson RC Jr, May GR, Bender CE. Percutaneous removal of kidney stones: review of 1000 cases. *J Urol*.1985;134:1077-90.
7. Reddy PK, Hulbert JC, Lange PH, et al. Percutaneous removal of renal and ureteral calculi: experience with 400 cases. *J Urol* 1985;134:662-7.
8. Valdiva UJG, Valer J, Villarroya S, et al. Why is percutaneous nephroscopy still performed with patient prone? *J Endourol* 1990;4:269-73.
9. Thuroff JW, Alken P. Ultrasound for renal puncture and fluoroscopy for tract dilation and catheter placement: a combined approach. *Endourology* 1987;2:1-4.
10. Valdiva UJG, Gerhold JV, Lopex JAL, Vet al. Technique and complications of percutaneous nephroscopy: experience with 557 patients in the supine position. *J Urol* 1998;160:1975-9.